Multidisciplinary Sciences Reports

Review article

INFRARED THERMOGRAPHY IN THE EARLY DIAGNOSIS OF PRESSURE INJURY AND ITS COMPLICATIONS: A review

1 Cinthya Kelly Bastos Freire Nogueira cinthyafreirenogueira@gmail.com

2 Mayara Francisca Barbosa Caruta mayaracaruta@hotmail.com

2 Sâmila Rociene Nunes Melo samilanunez@gmail.com

2 Doayne Gabrielly Rodrigues Senna doaynesenna@outlook.com

3 Luis Eduardo Maggi luis.maggi@ufac.br

1 Professor at the University Center (UNIMETA), Rio Branco, Acre, Brazil

2 Physiotherapy Student at the University Center (UNIMETA), Rio Branco, Acre, Brazil

3 Professor of Biophysics at the Center for Biological and Nature Sciences – CCBN, Universidade Federal do Acre – UFAC, Rio Branco, Acre, Brazil



ABSTRACT

Introduction: Lesion per Pressure (LPP) is a region of the human body where there is a process of ischemia due to prolonged pressure on soft tissues and especially bone prominences. The thermographic camera has become a feasible instrument for pathology diagnosis. Objective: To verify through bibliographical review whether infrared thermography is able to diagnose early stages of LPP, detect its progression to deep tissue injury, other complications and also verify its use in the healing process. Method: The study is an integrative literary review, developed through the search of articles dated from 2006 to 2017. Results: The articles selected for bibliographic review were divided according to their objectives. Thus, two groups were created. Discussion: It is identified that there is an inconsistency in stablishing the temperatures that increase the worsening or healing of LPP, the authors cannot agree on this issue, but in relation to thermography the results are meaningful since all studies show that thermography serves as an effective method for LPP monitoring. More research is needed, seeking to define, among other things, application, and evaluation protocols for thermography in LPP.

KEYWORDS: Thermography. Pressure Ulcers. healing.

RESUMO

Introdução: A Lesão por Pressão (LPP) consiste em uma região do corpo humano onde houve um processo de isquemia em decorrência da pressão prolongada sobre tecidos moles e principalmente proeminências ósseas. A câmera termográfica tornou-se um instrumento factível para diagnóstico de doenças. Objetivo: verificar através da bibliografia se a termografia infravermelha é capaz de diagnosticar precocemente estágios iniciais da LPP, detectar sua evolução e ainda verificar sua utilização no processo cicatricial. Método: trata-se de uma revisão literária integrativa, desenvolvido através da pesquisa de artigos datados de 2006 a 2017. Resultados: Os artigos (em inglês e português) selecionados para revisão bibliográfica foram divididos de acordo com seus objetivos. Desta forma, foram criados dois grupos. Discussão: Nota-se que existe inconsistência em relação às temperaturas que favorecem a piora ou melhora da LPP, os autores não conseguem entrar em acordo nessa questão. Porém, em relação à termografia, os resultados são significativos, já que todos os estudos mostram que a termografia serve como método eficaz para monitoramento de LPP. Mais pesquisas são necessárias, buscando definir, entre outras coisas, protocolos de aplicação e avaliação de termografias em LPP.

PALAVRAS-CHAVE: termograma. úlcera por pressão. cicatrização

INTRODUCTION

Lesion per Pressure (LPP) is an ischemic process that occurs as a result of prolonged pressure on soft tissues and especially bony prominences (1). In April 2016, the American National Pressure Ulcer Advisory Panel - (NPUAP) replaced the term ulcer by Lesion per Pressure – LPP (2).

The main factors that contribute to the development of this type of lesion can be divided into two groups: 1) Intrinsic factors: related to the clinical presentation of the patient, such as age, nutritional status, hypotrophy, obesity, sensory loss, reduced mobility, and edema (3). 2) Extrinsic factors: all those related to the mechanism of LPP formation from the external environment such as: microclimate, inadequate mattress, use of incorrect bedding, friction, shear, loss of fecal or urinary continence and contact pressure on bone prominence (4–6).

Non-staging LPP is characterized by full-thickness skin loss and non-visible tissue loss. Deep tissue pressure injury presents with intact or non-intact skin with a persistent non-blanchable dark red, brown, or purple area (9).

In Brazil, the incidence rate of Pressure Injuries ranges from 19% to 39.8% (10). LPP commonly affect the sacral region with an incidence from 29.5% to 35.8%. The calcaneus comes in second place, with a variation from 19.5% to 27.8% and, in third place, the trochanteric region, with an incidence between 8.6% and 13.7% (3).

It is estimated that approximately 600,000 patients in hospitals in the United States evolve to death due to secondary complications related to LPP, with a treatment cost of 11 billion dollars (10).

Classification can be made according to the extent of tissue damage (Figure 1): Stage 1: non-blanchable erythema on intact skin; Stage 2: partial skin loss with exposed dermis and blister with ruptured or intact serous exudate (2); Stage 3: full-thickness skin loss with exposure of adipose tissue (7); Stage 4: extensive tissue loss and necrosis of muscles, bones, and tendons (8).

Figure 1. Stages of Pressure Injury.

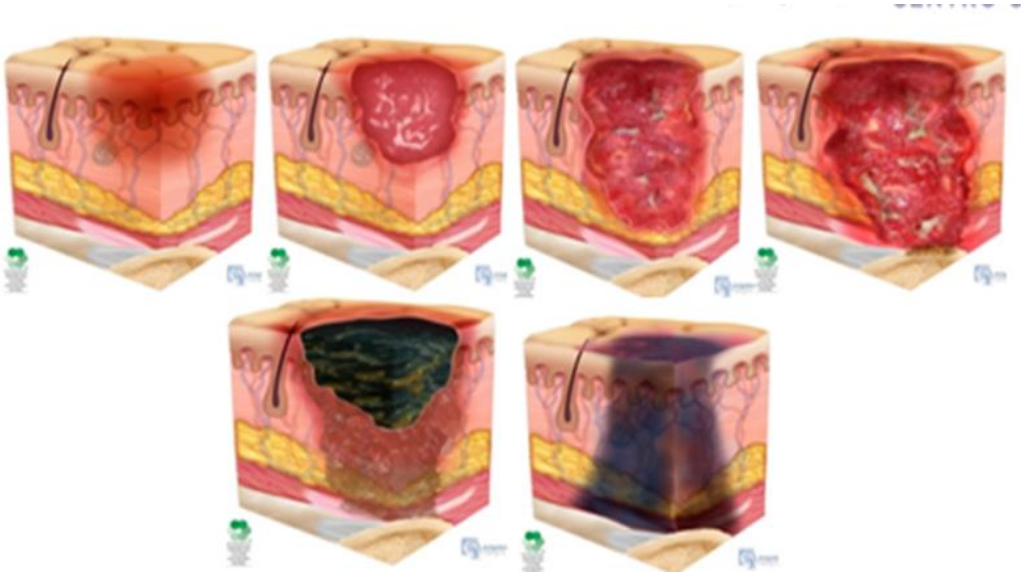

Source: MORAES et. al., 2016, p2295-22989 (Adapted).

Currently, health professionals use the scales of Gosnell, Andersen, Norton, Waterlow and the Braden Scale (BS) to identify the risk of developing injuries (11). This last scale has been widely used in the United States and, in 1999, its use was validated in Brazil, since then it has been applied in several Brazilian institutions (12).

Infrared thermography uses the heat signature to measure and provide a visual map of skin surface temperature. It is also important to emphasize that recorded skin temperatures may represent heat transferred through multiple layers of tissue to the skin. To interpret thermographic images and thermal measurements, a basic understanding of the physiological mechanisms of skin blood flow and the factors that influence heat transfers to the skin must be considered to assess this dynamic process (13). Temperatures vary with local blood supply and clinical abnormality (14).

The emission of infrared radiation from a body is captured by a camera with special sensors. This radiation is processed by commercial software, forming thermal images (thermograms), in which the spatial distribution of temperature is represented by a color code to be analyzed. Thermal imaging is non-invasive, obtained without direct contact with the patient, and is therefore safe. Furthermore, its assessment is objective (quantified), which is a clear advantage over subjective tests (15).

Figure 2 - **Left**: FLIR E6 Infrared Camera. **Right**: Thermographic Image and Color Scale. Myofascial Pain Syndrome (MPS)

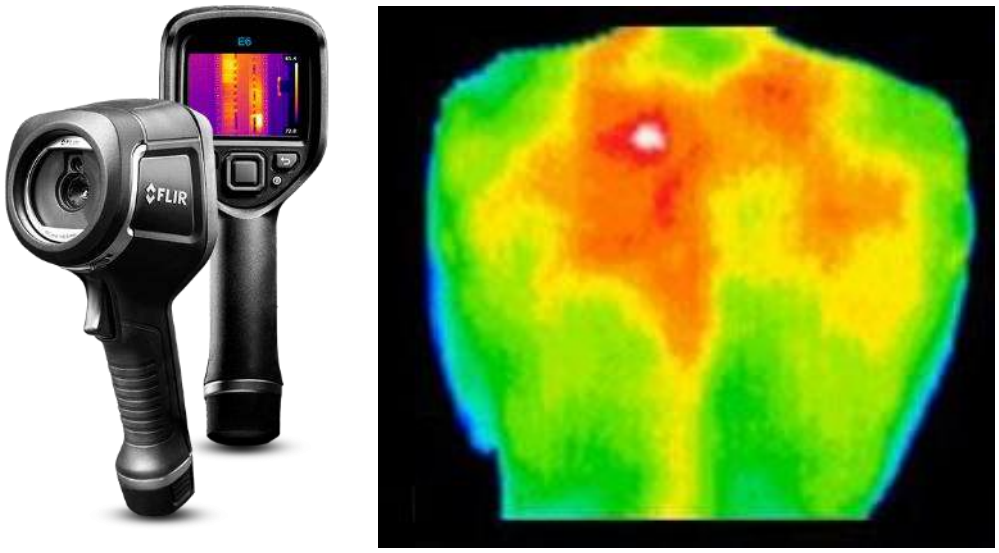

Source (Left): https://www.flir.com.br/support/products/e6/#Overview

Source (right): https://www.infraredmed.com/termografia-usada-no-tratamento-da-dor-miofascial/

Considering that thermography can serve as a means of diagnosing and evaluating LPP, much has been questioned about the effectiveness of the method. However, studies that report the use of infrared thermography applied to Pressure Injury are scarce. New knowledge on this topic can be of great contribution to health. Thus, the objective of this article is to verify, through a bibliographic review, if infrared thermography can diagnose early stages of LPP, detect its evolution to a deep tissue injury or other complications and verify its use in the healing process.

MATERIAL AND METHODS

This is an integrative literary review, developed through the search of scientific articles dated from 2007 to 2018, with searches carried out in the following databases: SCIELO, PUBMED, GOOGLE SCHOLAR, MEDLINE, LILACS and BVS. The following keywords were used: Thermography in Medicine, Pressure Injury, Pressure Ulcer, Thermography and Pressure Ulcers, Complications in bedridden

patients and Prevention of Pressure Injury.

From the 80 articles captured, 28 were filtered for initial research and 52 were excluded. After applying the inclusion and exclusion criteria, only 11 articles dating from 2006 to 2017 were obtained, which were used in the results and discussion (Figure 3). Articles in English and Portuguese that cited thermography associated with Pressure Injury were included in this literature review. Articles on thermography applied to civil engineering, veterinary medicine, as well as studies that related thermography applied to other diseases and sports injuries were excluded.

Figure 3 - Classification chart of articles selection for the research.

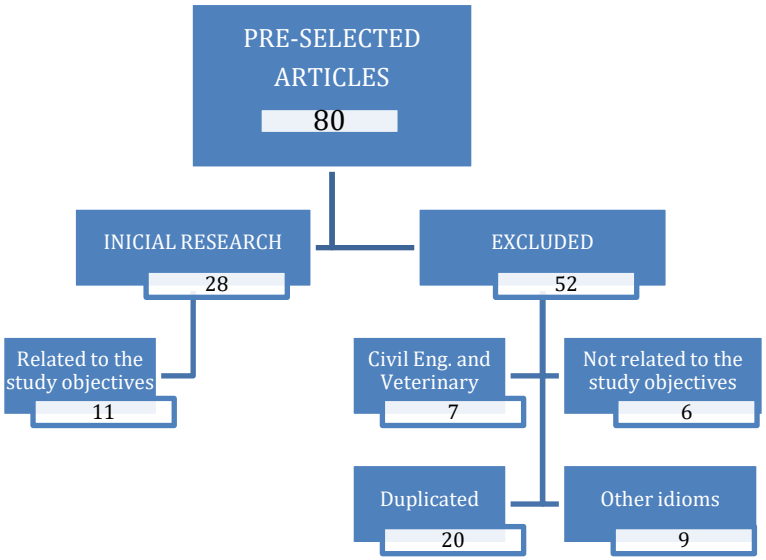

RESULTS AND DISCUSSION

The articles selected for literature review were divided according to their objectives. In this way, two groups were created, the first is related to the application of infrared thermography as an early diagnosis of lesion per pressure at an early stage. The second refers to the detection of complications and healing through thermograms. Five articles were selected for the first group and six articles included in the second, totaling eleven articles (Table 1).

Table 1 – Classification of the 11 articles according to objectives, title, year and author(s).

OBJECTIVE	TITLE	YEAR	AUTHORS
Diagnostic Thermography	Mechanical system to prevent pressure ulcers in wheelchair users (Portuguese)	2006	Godke et al.
	Improving the detection of pressure ulcers using the TMI ImageMed system.	2011	Judy, et al.
	Thermal Images Enhance Pressure Ulcer Risk Detection	2014	Bolton, L.
	Heat transfer model for deep tissue injury: A step towards an early thermographic diagnostic	2014	Akanksha Bhargava, Arjun Chanmugaman d Cila Herman
	Long term monitoring of a pressure ulcer risk patient using thermal images	2017	Stephanie L. Bennett; Rafik Goubran and Frank Knoefel
Thermography in the Detection of Complications and Healing	Predicting delayed pressure ulcer healing using thermography: A prospective cohort study	2010	Nakagami et al.
	Combination of thermographic and ultrasonographic assessments for early detection of deep tissue injury	2012	Higashino et al.
	Using temperature of Pressure-related Intact discolored areas of skin to detect deep tissue Injury: an observational, retrospective, Correlational study	2012	Farid et al.
	Handy thermography for bedside evaluation of pressure ulcer	2013	Yamamoto et al.
	Evaluation of healing of pressure ulcers through thermography: A preliminary study	2015	Chaves et al.
	Lower temperature at the wound edge detected by thermography predicts undermining development in pressure ulcers: a pilot study	2016	Kanazawa et al.

Diagnostic Thermography

In the study by Godke and Nohama (2006), an infrared thermographic camera was used to identify points of higher and lower temperature (17). The main objective in this case was to verify if the points marked as critical for the emergence of LPP were correct. For this, a healthy volunteer remained seated for one hour in the wheelchair and, after this period, the final thermogram was recorded. Infrared thermography determined that the coccyx was the main region affected by ischemia, later followed by the ischial tuberosity regions.

In a 2011 survey, Judy et al. (18) evaluated a new infrared imaging device and an intelligent software interface that could identify anatomical sites at risk of developing pressure Injury. The Branden Scale (BS) was also applied. Only five participants of the 100 selected developed an early-stage Pressure Injury. The infrared imaging device predicted all five participants, the lesions involved the sacrum and calcaneus. BS correctly identified three of the five participants.

Judy et al. (2011) (18) and Bolton (2014) (19) were the only studies found in our review that compared the Braden Scale and infrared thermography. It is important to say that the imaging technique obtained better results in the detection of anatomic risk points, when compared to the SB. With this, it is possible to say that thermography may be more effective than the current predictive method.

The study carried out by Bolton in 2014 (19) evaluated, using an infrared camera, the risk of patients developing LPP. The bone prominences evaluated were the sacrum and the calcaneus. The Braden Scale was also applied. Participants were divided into high and low risk, all those classified as high risk by thermography and BS developed LPP at an early stage, but two individuals classified as low risk by the Braden Scale also ended up developing it, which did not happen in the imaging technique.

Bhargava et al. (2014) (20) wanted to detect possible deep tissue injury, according to the authors, there is inconsistency in relation to the temperature observed for the evolution of LPP. For this, they evaluated both ischemia and hyperemia, then concluded that both processes are involved in the emergence of deep tissue injury and suggest further investigation to determine the time scale for the increase and decrease in temperature, however, they state that thermography

can be used as a means of early diagnosis of deep tissue injury.

Bennet et al. (2017) focused on identifying individuals who could develop LPP in the malleolus region, using a FLIR® infrared camera (21). They evaluated one patient for one hundred and twelve days, on the sixth day the patient complained of pain in the right malleolus and a small mark was thermographically visible. They observed different temperatures in this region and around it, this difference consisted of erythema followed by ischemia, thus detecting stage 1 LPP. The patient received intervention reaching the final evaluation without showing any visible changes in the thermography (21).

According to Judy et al. (2011) (18), thermography can become a promising method in the prevention of LPP and, through the identification of anatomical risk points, intervention measures can be taken to prevent the progression of LPP. Reinforcing this hypothesis, we have the study by Bennet et al. (2017), who detected the risk, took intervention measures, and had good results (21). Bolton (2014) states that thermography provides valuable data on risk sites for the appearance of LPP, however he states that it is always necessary to make a clinical evaluation of the patient (19).

All the cited articles report the application of thermography as an early diagnosis of LPP and confirm that it is capable of identifying the anatomical regions frequently affected, such as: the coccyx, ischial tuberosity, sacrum, malleolus, calcaneus and trochanteric region, the latter four being often cited in other literature such as Fachinetti and Fernandes (2017); Silvestre and Holsbasch (2012), due to the high incidence (3,22). These regions are also found in the studies by Nakagami et al. (2010), Higashino et al. (2012), Chaves et al. (2015) and Kanazawa et al. (2016), who also identified these anatomical points, but in patients with already installed lesions (15,23–25).

Thermography in the Detection of Complications and Healing

Nakagami et al. (2010) (23) evaluated whether thermography was able to define the healing prognosis and identify latent stage 2 and 4 LPP infection in the greater trochanter and sacrum. Thirty-three patients were investigated, of these, seventeen had lesions with milder temperatures in the wound bed and had a good

prognosis, while sixteen who had high temperature in the wound bed were associated with infectious processes. According to the authors, thermography can provide enough information to predict wound healing and identify latent infection.

Higashino et al. (2012) (24), in their investigation, made a combination of thermographic and ultrasound assessments to discover deep tissue damage. From the twenty-eight early-stage pressure injuries studied, twelve showed high temperatures in thermographic evaluations, which were associated with deep tissue injury in the sacrum, greater trochanter. With this, it was noted that thermography and ultrasound are non-invasive and efficient procedures and can be evaluated at the bedside. However, ultrasound requires more knowledge, thermography evaluates accurately, but does not provide depth data like ultrasound.

Farid et al. (2012) analyzed whether early-stage pressure injury could present a prognosis of evolution to deep tissue injury (26). For this, they sought to indicate which temperature favored the worsening of LPP. Thermographic images of 85 patients were obtained using a FLIR i7 handheld device. At the end of the study, lesions that had low temperatures in the wound bed progressed to tissue damage significantly more than those that had high temperatures. The authors support the use of thermography in this regard, according to them thermography is a promising technique to detect deep tissue injury. Further studies on the technique are suggested.

According to Bhargava et al. (2014), there are controversies regarding the temperature that predisposes the evolution of LPP to deep tissue injury (20). This fact was noted in the studies by Higashino et al. (2012), who detected high temperature in the evolution of LPP (24), while Farid et al. (2012) found a high proportion of aggravation in injuries with low temperatures (26). It is necessary to consider that the sample by Farid et al. (2012), with 85 individuals, was larger than the sample collected by Higashino et al. (2012), who studied 28 injuries. Perhaps this factor explains the difference in results. Even with this divergence in relation to temperature, these investigations had satisfactory results in the detection of deep tissue injury by thermography.

Yamamoto et al. (2013) (27) adopted the use of infrared thermography to examine five pressure injuries in the sacral region of some individuals. It was verified that three exhibited low temperatures in the wound bed in relation to the surrounding

region, resulting in the progression of the lesion. The two that had no temperature difference were linked to a good prognosis. According to them, thermography serves as an evaluation method for LPP and further studies are needed to judge the accuracy of this technique.

Chaves et al. (2015) (25) aimed to investigate whether thermography could be used as a method of evaluating the healing of pressure injuries in the sacral region of eight patients. Thermograms were obtained with a FLIR® camera. Patients who had lower temperatures of 32-33 °C had an increase in the injured area. Those who had a higher temperature, 34-35 °C, had the injured area reduced. According to the authors, thermography is used to assess wound healing and suggest further studies.

According to Chaves et al. (2015) (25), there is an adequate temperature threshold for healing, which is around 32 to 36 °C, the lower temperature causes healing to be delayed. On the other hand, Nakagami et al. (2010) (23) state that a lower temperature is associated with healing, while a higher temperature is associated with infections.

Kanazawa et al. (2016) (28) classified twenty-two individuals with lesions in stages 3 and 4, aiming to predict the risk of complications. For this, they analyzed whether there would be a decrease in temperature at the edges of the lesion, in the regions of the coccyx, sacrum and greater trochanter. After evaluation of thermographic images, eleven patients had a lower temperature. Of these, ten evolved with complications. Although the authors did not use ultrasound, they suggest its use in association with thermography and state that the assessment of thermal imaging can provide data on possible complications.

The study by Kanazawa et al. (2016) and Yamoto et al. (2013) did not clearly report which complications they sought to identify, but they managed to complete their investigations, when they found complications in lesions that presented low temperatures with the use of infrared thermography. The divergence between these authors is in relation to the location of this temperature, since Kanazawa et al. (2016), found low temperature at the edges of the lesion and Yamoto et al. (2013) detected lower temperature in the wound bed. In our review, the investigations by Higashino et al. (2011) and Kanazawa et al. (2016) suggest the combination of thermography and ultrasound, with the justification that the infrared imaging technique does not offer depth data, even so they claim that thermography serves as

a good evaluative instrument.

It is noted again that there is inconsistency in relation to the temperature that favors the worsening or improvement of LPP, the authors cannot agree on this issue, however, in relation to thermography, the results are significant, since all studies show that the thermography serves as an effective method for monitoring LPP.

FINAL CONSIDERATIONS

The eleven studies reviewed indicate that thermography is an innovative method, without risks to the subject and with great evaluative potential in several stages. Through this imaging technique, it is possible to verify points with the risk of developing LPP, monitor possible complications and verify the healing prognosis, thus improving the quality of life of predisposed or affected individuals. It is important to note that this study was limited by the small number of articles reviewed and the lack of published studies on the topic addressed. Further research is suggested to confirm the efficiency of this imaging technique and a study to determine a standard protocol to be followed for the application of thermography and the evaluation of images in relation to lesions per pressure.

REFERENCES

1. Souza CT de, Prado RT. A Utilização da escala de Braden na UTI para prevenção de úlcera por pressão. Revista EDUC-Faculdade de Duque de Caxias [Internet]. 2016;03(1):31–50. Available from: https://comum.rcaap.pt/handle/10400.26/11076

2. Moraes JT, Borges EL, Lisboa CR, Cordeiro DCO, Rosa EG, Rocha NA. Conceito e classificação de lesão por pressão: atualização do National Pressure Ulcer Advisory Panel. Revista de Enfermagem do Centro-Oeste Mineiro. 2016;6(2):2292–306.

3. Facchinetti JB, Fernandes FP. Recursos utilizados por Fisioterapeutas para Prevenção e Tratamento de Lesão por Pressão. Id on Line REVISTA DE PSICOLOGIA. 2017;11(37):421–35.

4. Moro A, Maurici A, do Valle JB, Zaclikevis VR, Kleinubing H. Assessment of patients with pressure sores admitted in a tertiary care center. Revista da Associacao Medica Brasileira. 2007;53(4):300–4.

5. Mendonça PK, Loureiro MDR, Ferreira Júnior MA, Souza AS de. Ocorrência e fatores de risco para lesões por pressão em centros de terapia intensiva TT - Occurrence and risk factors for pressure injuries in intensive care centers. Rev enferm UFPE on line [Internet]. 2018;12(2):303–11. Available from: https://periodicos.ufpe.br/revistas/revistaenfermagem/article/view/23251/27794%0Ahttps://periodicos.ufpe.br/revistas/revistaenfermagem/article/view/23251/27793

6. de Souza TS, Maciel OB, Méier MJ, Danski MTR, Lacerda MR. Estudos clínicos sobre úlcera por pressão. Revista brasileira de enfermagem. 2010;63(3):470–6.

7. Constantin A, Moreira AP, Oliveira JL, Hofstätter LM, Fernandes L. Incidência de lesão por pressão em unidade de terapia intensiva para adultos. Revista ESTIMA. 2018;16:1–9.

8. Rocha SCG, Oselame GB, Mello MG da S, Neves EB. Comparação das escalas de avaliação de risco de lesão por pressão. Revista Brasileira de Pesquisa em Saúde/Brazilian Journal of Health Research. 2016;18(4):143–51.

9. Silva DRA, Bezerra SMG, Costa JP, Luz MHBA, Lopes VCAL, Nogueira LT. Curativos de lesões por pressão em pacientes críticos: análise de custos. Pressure ulcer dressings in critical patients: A cost analysis. 2017;51:1–8.

10. HRMS HR de MG do S. Protocolo de Prevenção de LPP [Internet]. Campo Grande, MS; 2017. Available from: http://www.hospitalregional.ms.gov.br/wp-

content/uploads/sites/129/2018/01/PROTOCOLO-DE-LPP.pdf

11. Bavaresco T, Medeiros RH, Lucena A de F. Implantação da Escala de Braden em uma unidade de terapia intensiva de um hospital universitário. Revista gaúcha de enfermagem / EENFUFRGS. 2011;32(4):703–10.

12. Serpa LF, Santos VLC de G, Campanili TCGF, Queiroz M. Validade preditiva da escala de Braden para o risco de desenvolvimento de úlcera por pressão, em pacientes críticos. Revista Latino-Americana de Enfermagem [Internet]. 2011 [cited 2021 Dec 7];19(1):1–8. Available from: http://www.scielo.br/j/rlae/a/pvfjgRw3q844YGt4LHMqNpQ/abstract/?lang=pt

13. Diakides NA, Bronzino JD. Medical Infrared Imaging. New York: CRC Press; 2008.

14. Guimaraes CMD de S, Brioschi ML, Neves EB, Balbinot LF, Teixeira MJ. IMAGEM INFRAVERMELHA NO DIAGNÓSTICO DAS DOENÇAS DOS PÉS. PAN AMERICAN JOURNAL OF MEDICAL THERMOLOGY. 2018;4:7–14.

15. Kanazawa T, Nakagami G, Goto T, Noguchi H, Oe M, Miyagaki T, et al. Use of smartphone attached mobile thermography assessing subclinical inflammation: A pilot study. Journal of Wound Care. 2016;25(4):177–82.

16. Côrte ACR e., Hernandez AJ. Termografia médica infravermelha aplicada à medicina do esporte. Revista Brasileira de Medicina do Esporte. 2016;22(4):315–9.

17. Godke F, Nohama P. Sistema mecânico para evitar úlceras de pressao em usuários de cadeiras de rodas. Revista Tecnologia e Humanismo [Internet]. 2006;20(30):111–23. Available from: https://periodicos.utfpr.edu.br/rth/article/view/6382

18. Judy D, Brooks B, Fennie K, Lyder C, Burton C. Improving the detection of pressure ulcers using the TMI ImageMed system. Advances in skin & wound care. 2011;24(1):18–24.

19. Bolton L. Thermal Images Enhance Pressure Ulcer Risk Detection. Wounds. 2014;26(12):360–2.

20. Bhargava A, Chanmugam A, Herman C. Heat transfer model for deep tissue injury: A step towards an early thermographic diagnostic capability. Diagnostic Pathology. 2014;9(1):1–18.

21. Bennett SL, Goubran R, Knoefel F. Long term monitoring of a pressure ulcer risk patient using thermal images. In: 39th Annual International Conference of the IEEE Engineering in Medicine and Biology Society (EMBC). 2017. p. 1461–4.

22. Silvestre JT, Holsbach DR. Atuação fisioterapêutica na úlcera de pressão : uma revisão de literatura. Revista Fafibe On-Line. 2012;V(5):1–12.

23. Nakagami G, Sanada H, Iizaka S, Kadono T, Higashino T, Koyanagi H, et al. Predicting delayed pressure ulcer healing using thermography: A prospective cohort study. Journal of Wound Care. 2010;19(11):465–72.

24. Higashino T, Nakagami G, Kadono T, Ogawa Y, Iizaka S, Koyanagi H, et al. Combination of thermographic and ultrasonographic assessments for early detection of deep tissue injury. International Wound Journal. 2014;11(5):509–16.

25. Chaves MEA, da Silva FS, Soares VPC, Ferreira RAM, Gomes FSL, de Andrade RM, et al. Evaluation of healing of pressure ulcers through thermography: A preliminary study. Revista Brasileira de Engenharia Biomedica. 2015;31(1):3–9.

26. Farid KJ, Winkelman C, Rizkala A, Jones K. Using temperature of Pressure-related Intact discolored areas of skin to detect deep tissue Injury: an observational, retrospective, Correlational study. Ostomy Wound Management. 2012;58(8):30–1.

27. Yamamoto T, Yamamoto N, Azuma S, Todokoro T, Koshima I. Handy thermography for bedside evaluation of pressure ulcer. Journal of Plastic, Reconstructive and Aesthetic Surgery [Internet]. 2013;66(7):e205–6. Available from: http://dx.doi.org/10.1016/j.bjps.2013.02.005

28. Kanazawa T, Kitamura A, Nakagami G, Goto T, Miyagaki T, Hayashi A, et al. Lower temperature at the wound edge detected by thermography predicts undermining development in pressure ulcers: a pilot study. International Wound Journal. 2016;13(4):454–60.