Multidisciplinary Sciences Reports

Artigo

Occurrence of hematozoa in armadillo (*Dasypus novemcintus*, Linnaeus, 1758) in Rio Branco, Acre, Brazil

1	Vanessa Lima de Souza	limasouzavannessa@gmail.com	
1	Giovana Barbosa Morais	gih.barbosa1@gmail.com	
1	Ester Nascimento da Costa	ester.nascimento@sou.ufac.br	
1	Irlla Narel Leão Cunha de Oliveira	irllanarel@gmail.com	
2	Luis Eduardo Maggi	luis.maggi@ufac.br	
3	Rogerio de Freitas Lacerda	rogerio.lacerda@ufac.br	
2	Francisco Glauco de Araújo Santos	francisco.araujo@ufac.br	

1 Laboratório de Patologia e Vida Silvestre. Universidade Federal do Acre, Rio Branco- AC, Brazil
2 Centro de Ciências Biológicas e da Natureza –CCBN, Universidade Federal do Acre – UFAC, Acre, Brazil
3 Laboratório de Bioquímica. CCBN - Universidade Federal do Acre, Rio Branco - AC, Brazil.

ABSTRACT

The armadillo (*Dasypus novemcinctus*) is widely distributed and has a relevant parasitic fauna, being a potential disseminator of zoonoses and playing a significant role in the epidemiology of parasitic diseases. This study analyzed blood samples from individuals of the species to investigate the presence of hematozoa, the percentage of leukocytes and erythrocyte morphometry. The specimens were captured with the aid of sniffer dogs, manually removed from their burrows, restrained, identified and submitted to blood collection. Five thin-drop smear slides were prepared, three stained with LABORCLIN® Rapid Panotic and two with Giemsa RenyLab®. The analysis took place at the Wildlife Support Laboratory of the Federal University of Acre, where the slides were observed under light microscopy. The erythrocyte description included the count of 1,000 erythrocytes, photographed by the LAZ EZ software. The percentage of leukocytes was determined by counting 100 cells, considering nuclear morphology. The results indicated that the percentages of leukocytes were similar to those of other mammals, and the mean diameter of erythrocytes was 6.9 µm. It was found that 85.7% of the animals were parasitized, with a prevalence of 28.57% for *Plasmodium* and *Trypanosoma*. The record of *Plasmodium sp*. in *D. novemcinctus* is unprecedented, highlighting the relevance of this study for public health and conservation of the species, in addition emphasizing the importance of monitoring wildlife in epidemiological surveillance.

KEYWORDS: Wild animals. Blood smears. Light microscopy. *Plasmodium*. *Trypanosoma*.

RESUMO
O tatu (*Dasypus novemcinctus*) é amplamente distribuído e apresenta uma fauna parasitária relevante, sendo um potencial disseminador de zoonoses e desempenhando um papel significativo na epidemiologia de doenças parasitárias. Este estudo analisou amostras de sangue de indivíduos da espécie para investigar a presença de hematozoários, a porcentagem de leucócitos e a morfometria eritrocitária. Os espécimes foram capturados com o auxílio de cães farejadores, retirados manualmente das tocas, contidos, identificados e submetidos à coleta de sangue. Foram confeccionadas cinco lâminas de esfregaço de gota fina, sendo três coradas com LABORCLIN® Rapid Panotic e duas com Giemsa RenyLab®. A análise ocorreu no Laboratório de Apoio à Fauna Silvestre da Universidade Federal do Acre, onde as lâminas foram observadas sob microscopia de luz. A descrição eritrocitária incluiu a contagem de 1.000 eritrócitos, fotografados pelo software LAZ EZ. A porcentagem de leucócitos foi determinada pela contagem de 100 células, considerando a morfologia nuclear. Os resultados indicaram que as porcentagens de leucócitos foram semelhantes às de outros mamíferos, e o diâmetro médio dos eritrócitos foi de 6,9 µm. Foi constatado que 85,7% dos animais estavam parasitados, com prevalências de 28,57% para *Plasmodium* e *Trypanosoma*. O registro de *Plasmodium sp*. em *D. novemcinctus* é inédito, ressaltando a relevância deste estudo para a saúde pública e conservação da espécie, além de destacar a importância do monitoramento da fauna silvestre na vigilância epidemiológica.

Palavras-chave: Animais selvagens. Esfregaços de sangue. Microscopia de luz. *Plasmodium*. *Trypanosoma*.

INTRODUCTION

Wild animals are considered reservoirs of pathogens that can be transmissible to humans, giving rise to new parasite-host interactions (1–3). The ecological vision emphasizes that wild animals are important agents and have high complexity for public health, acting as bioindicators of environmental quality and sentinels, through anthropization in different parts of the world (2–5).

In recent decades, several studies have found that increased contact between humans and wild animals has enabled the spread of various infectious agents, increasing the risk of transmission of zoonoses, including malaria and Chagas disease. (1,4,6). Chagas disease is an anthropozoonosis caused by *Trypanosoma cruzi*, in the state of Acre alone there were 25 confirmed cases in 2016 (7)

Armadillos have a vast parasitic fauna, described as spreaders of zoonosis, thus being relevant to the epidemiology of parasitic diseases (8). The nine-banded armadillos (*Dasypus novemcinctus*, Linnaeus, 1758) is considered eurytopic, tolerant of wide variation in one or more environmental factors, reported to occur from the south of the United States to southern Brazil (Gomes, 2010) and the Amazon region presents favorable conditions for the transmission of malaria caused by *Plasmodium falciparum*, considered an endemic area for the disease (9). The nine-banded armadillo *D. novemcinctus* belongs to the family Dasypodidae, Cingulata Order which, together with anteaters and sloths, comprises the superorder Xenarthra (10).

D. novemcinctus is described in several literature as a sentinel species for several infectious agents, being considered an important bioindicator in the ecological niche they inhabit (11). The presence of hemoparasites in *D. novemcinctus* has significant implications for public health, as these pathogens may have zoonotic potential, facilitating the transmission of diseases to human populations. The detection of

Plasmodium sp. in this species suggests that armadillos could act as reservoirs or intermediate hosts, contributing to the maintenance of parasite cycles in the wild. This is particularly concerning in regions where malaria is endemic. Understanding the role of armadillos in the transmission dynamics of these parasites can improve disease surveillance and mitigating zoonotic events (2,3,11).

Given this context, the objective of this study was to describe and morphologically identify the hematozoa found in *D. novemcinctus* as well as to know the leukocyte percentage and morphometry of erythrocytes from the nine-banded armadillo, captured at Rio Branco city, State of Acre.

MATERIAL AND METHODS

Authorizations

The study was carried out under authorization from the Biodiversity Authorization and Information System, SISBio N. 51512-1. Armadillo captures were approved by the Ethics Committee on the Use of Animals-CEUA, of the Federal University of Acre, under process N.23107.016721/2015-33.

Study area

The study was carried out in the rural area of the Rio Branco city (10°05'12.7"S 68°01'48.5"W). This municipality, capital of Acre state, has an equatorial climate (hot and rainy) with an average annual temperature of around 25 °C and rainfall of approximately 2,000 mm/year (INMET, 2018). Its natural vegetation is basically composed of open tropical forest (low plateaus and alluvial), with a great diversity of fauna and flora.

Capture of animals

The animals were captured with the aid of sniffer dogs and manual restraint, during the period from December 2015 to May 2016. Seven individuals of armadillos, *Dasypus novemcinctus* specimens, were captured, three adult females, three adult males and one male young, coming from Highway AC-090, Ramal do Barro Alto, Rio Branco, Acre, on the property of Mrs. Silvia Barbosa da Silva (10°05'12.7"S 68°01'48.5"W).

Sample collection

After manual restraint, the femoral vein was punctured using disposable material and a volume of 0.5 mL of blood was collected and stored in tubes with EDTA for subsequent preparation of blood smears.

Preparation of blood smears and microscopic evaluation

The samples were sent to the Pathology and Wildlife Support Laboratory, at the Federal University of Acre. Five thin smear slides were prepared from each animal. Three slides were stained with LABORCLIN® Rapid Panoptic and two with Giemsa RenyLab® and observed under light microscopy. The erythrocyte and leukocyte description were carried out by measuring the percentage and counting of 1,000 erythrocytes and 100 leukocytes, by identifying nuclear morphology. The identified hemoparasites were photographed using optical microscope LEICA DM750 (Leica ICC50 HD) and captured using the LAZ EZ software (Leica application suite 3.2.1) with attached camera.

RESULTS

The experiment consisted of examining seven individuals (62.5 % males and 37.5 % females; average weight 3.47 ± 0.32 kg). The leukocyte count reached an average total of 39 % neutrophils, 31 % monocytes, 19 % lymphocytes, 6 % basophils and 5 % eosinophils. The morphometric analysis of armadillo erythrocytes showed an average of 6.9 µm in diameter (Table 1).

Table 1 - Leucocyte differential counts (mean + 1 SD and range in parentheses) from *Dasypus novemcinctus* and *Chaetophractus villosus*.

Leucocyte differential counts	**Founds** *Dasypus novemcinctus* **(n = 08)**	**References*** *Chaetophractus villosus* **(n = 25)**
Neutrophils (%)	39	(28–77)
Eosinophils (%)	5	(0–9)
Basophils (%)	6	(0–6)
Lymphocytes (%)	19	(14–65)
Monocytes (%)	31	(3–13)

* (12).

In the present study, 85.7 % of the animals were parasitized, 40 % by *Plasmodium falciparum* (Figure 01), 40 % by *Trypanosoma cruzi* (Figure 02) and 20 % by both protozoa.

Figure 01: (A) Ring shape of *Plasmodium falciparum* (arrow). (B) *P. falciparum* gametocyte (arrow). Staining with LABORCLIN Rapid Panoptic (140X).

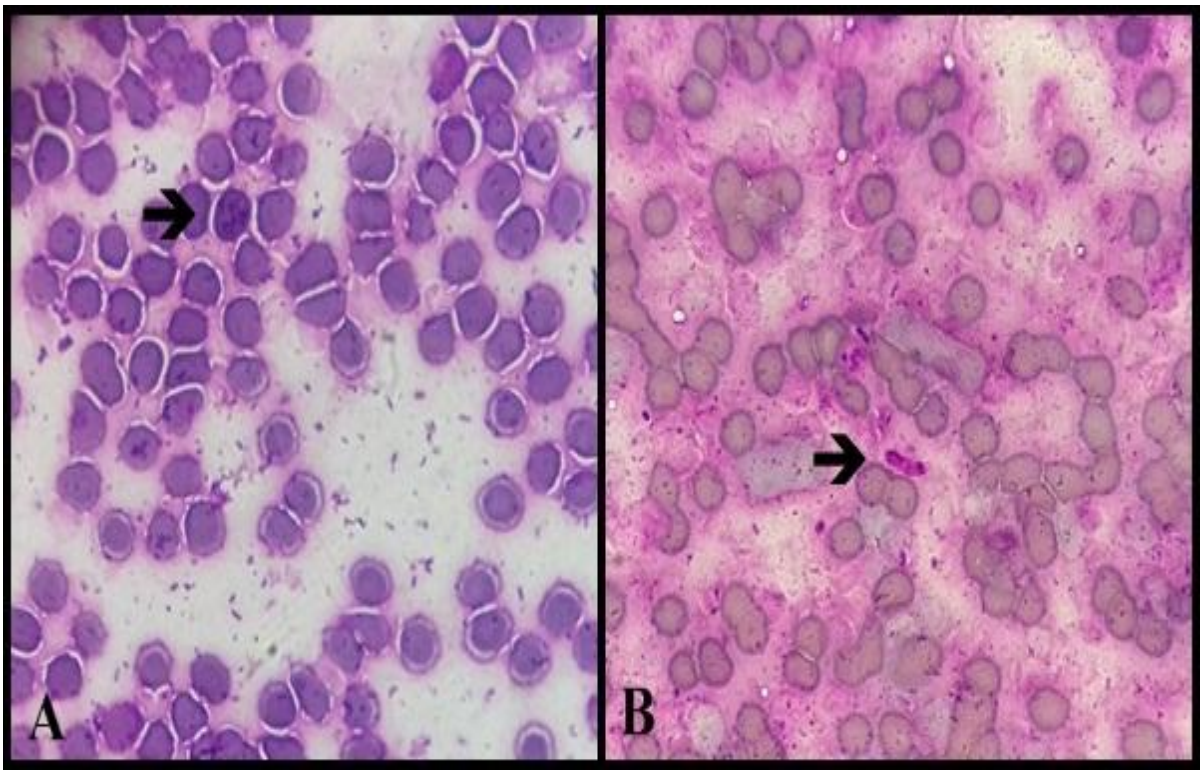

Figure 02: The nine-banded armadillos blood smear: (A) Hyper-stained *Trypanosoma cruzi* trypomastigote form (arrow); (B) Thin form of the protozoan (arrow); (C) Thin-shaped cluster of *T. cruzi*. (arrow) LABORCLIN Rapid Panoptic Staining (1,000X).

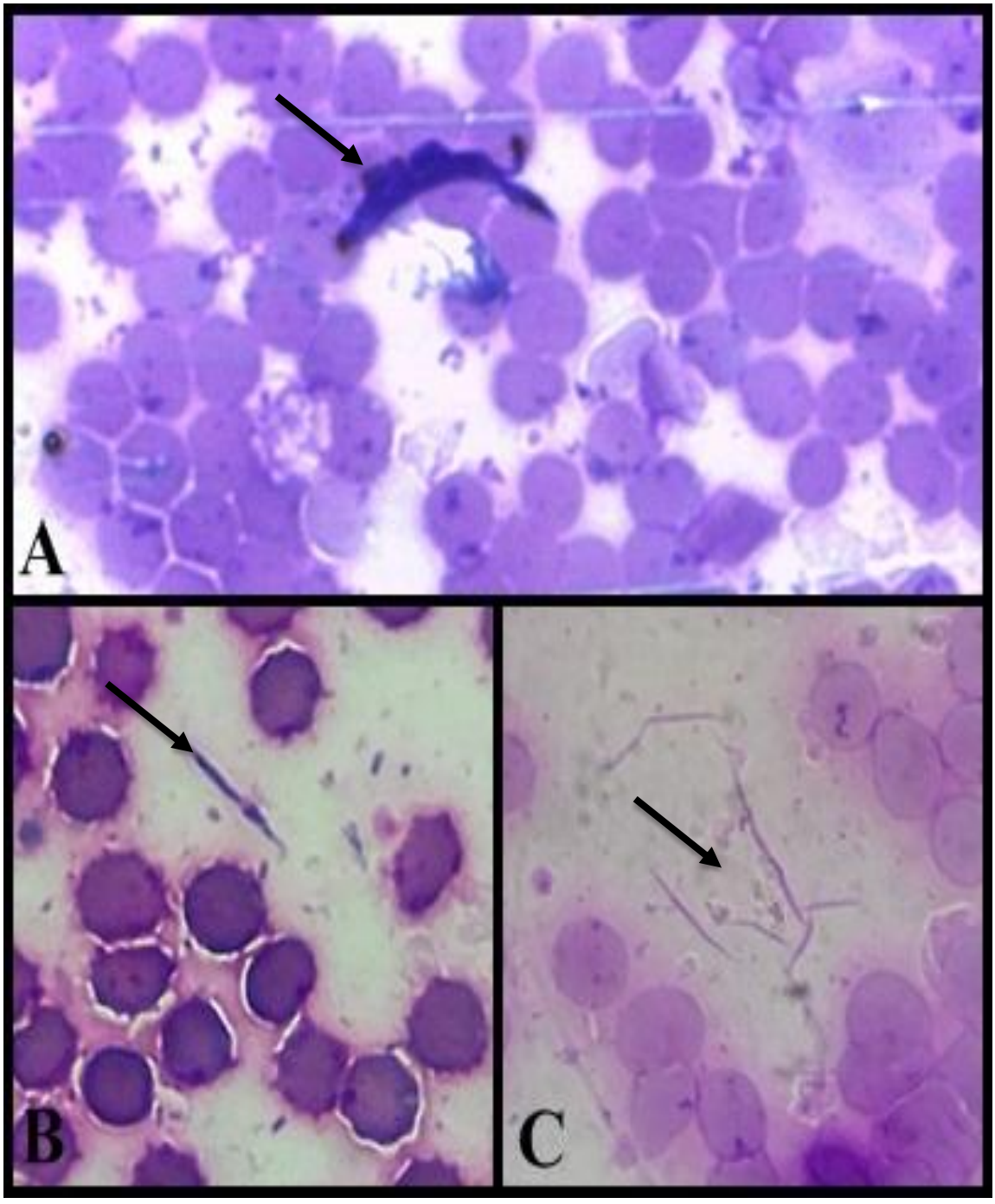

DISCUSSIONS

Understanding the role of armadillos in the transmission of parasites can enhance disease surveillance and help mitigate zoonotic events. In this context, the aim of this study was to describe and morphologically identify the hematozoa found in *D. novemcinctus*, as well as to analyze the leukocyte percentage and the erythrocyte morphometry of the nine-banded armadillo captured in Rio Branco, state of Acre, Brazil.

Microscopic analysis revealed that the leukocyte percentages and morphometry are equivalent to those found in other mammals of Cingulata order, showing no significant differences from normal levels (12).

The number of leukocytes was alike that in *D. hybridus* and the range is clearly smaller than in *D. novemcinctus*. A plausible explanation may be related to the large number of animals studied by Casanave and Polini (1999) (12). *D. hybridus* and the distribution is clearly smaller than in *D. novemcinctus* (12). The mean and variation values of neutrophils, basophils and lymphocytes were similar to those obtained by Cuba Caparo (1976) in *D. hybridus* (13), but clearly different from those found in *D. novemcinctus* by D'Addamio et al. (1978) (14). In the case of eosinophils, the mean and variation values were higher than those obtained for other armadillos. The differences observed between populations in relation to the number of eosinophils can be explained by the fact that the animals from Jacinto Arauz support a higher parasite load than those from Nueva Roma. The number of monocytes was much higher (31 %) than that observed for the species *C. villosus* (3 – 13 %), which may suggest a mucous inflammatory process, in a subclinical form (12).

In the present study, the protozoan *Plasmodium falciparum* is reported, the causative agent of the most virulent form of malaria in humans, infecting *D. novemcinctus* (nine-banded armadillo). *Plasmodium* sp. is the etiological agent of malaria, differentiating morphologically in vertebrate hosts and vector during its biological cycle, going through invasive and replication stages, interposed by a single phase of sexual development (9).

In the period from 2000 to 2011, an average of 422,858 cases of malaria were reported per year. More than 90 % were recorded in the Amazon Region. The states of Pará, Amazonas, Rondônia, Acre, Amapá and Roraima were those with the highest number of reported cases (15).

Approximately 33 species of *Anopheles* have been recorded for the Amazon Region and among these, *Anopheles darlingi* is considered the main one. Other species are considered secondary vectors and their participation in malaria transmission should be considered variable between locations (16).

Malaria is an acute febrile infectious disease caused by protozoa of the genus *Plasmodium* transmitted by the bite of an infected female mosquito of the genus *Anopheles* (16). This finding is important because the vector also has a zoophilic and anthropophilic diet, which may be a relevant factor for the spread of the protozoan (9).

Chagas disease, or American trypanosomiasis, is an anthropozoonosis caused by the protozoan *Trypanosoma cruzi*, whose vector, insects of the genus *Triatoma*, are popularly known as kissing bug (other genera of insect vectors: *Panstrongylus* and *Rhodnius*). In recent years, this disease has had an acute occurrence, especially in the Legal Amazon, through oral transmission. Among the three vector transmission cycles of *T. cruzi*, armadillos are included in the sylvatic cycle as reservoirs and are

among the main autochthonous representatives of the protozoan (17). In the present study, 40 % of armadillos were infected by *T. cruzi*.

It is known that contact between different species of animals can increase the movement of parasites, making infectious and parasitic diseases equally important from the point of view of conservation, which can lead to population decline or animal extinction (2).

Currently, *T. cruzi* is found circulating in nature among more than a hundred species of mammals distributed in seven different orders and dozens of vector species(18). As we know, Chagas disease is a clinical manifestation that can result from *T. cruzi* infection in humans, whose transmission occurs, in the vast majority of cases, by triatomine vectors. Other routes of infection are oral (by ingestion of food contaminated with the infective forms of the parasite), congenital, by blood transfusion or organ transplantation (18,19).

Silva and Drumond (2009) state that the armadillo is currently the second most hunted animal in the south of the State of Acre and occupies second place among the animals most appreciated for the flavor of its meat. The consumption of armadillo meat is common, especially in some places in the Amazon region and, when infected by the protozoan, handling the carcass and ingesting this undercooked game meat constitutes a source of infection for humans (19).

The epidemiological importance of these mammals is even greater if we consider that sloths, anteaters and armadillos are hunted and consumed in some areas of the country, such as the Amazon region, and that the manipulation of the carcass or the ingestion of the undercooked meat of infected animals can constitute sources of infection for humans(19).

CONCLUSION

The leukocyte percentages and the average diameter of erythrocytes do not differ much from the normal values of other mammals. Due to the wide distribution of the armadillo species and the proximity of these animals to inhabited places, it is necessary to know the possible blood parasites that use the armadillo as a reservoir, allowing the transmission of important zoonoses such as malaria and Chagas disease to humans. To date, no reports have been found listing the armadillo as a reservoir for *Plasmodium sp.*, in Acre states.

Acknowledgements

Federal University of Acre and CAPES for allowing the research to be carried out and Ms. Silvia Barbosa da Silva, who provided access to her private property to capture the animals.

Conflict of interests

There is no conflict of interest

REFERENCES

1. Fowler ME, Cubas ZS. Biology, medicine, and surgery of South American wild animals. Iowa State University Press; 2001. 536 p.

2. Daszak P, Cunningham AA, Hyatt AD. Anthropogenic environmental change and the emergence of infectious diseases in wildlife. Acta Trop [Internet]. 2001;78:103–16. Disponível em: www.parasitology-online.com

3. Daszak P, Cunningham AA, Hyatt AD. Emerging infectious diseases of wildlife - Threats to biodiversity and human health. Vol. 287, Science. 2000.

4. Thompson RCA, Kutz SJ, Smith A. Parasite zoonoses and wildlife: Emerging issues. Int J Environ Res Public Health. 2009;6:678–93.

5. Rhimi W, Sgroi G, Aneke CI, Annoscia G, Latrofa MS, Mosca A, et al. Wild Boar (Sus scrofa) as Reservoir of Zoonotic Yeasts: Bioindicator of Environmental Quality. Mycopathologia. 1º de junho de 2022;187(2–3):235–48.

6. Fernandes W de OB. Detecção sorológica da leptospirose, toxoplasmose e leishmaniose em tatus-peba (Euphractus sexcinctus) de vida livre [MESTRADO]. [MOSSORO-RN]: UFERSA; 2015.

7. de Oliveira GF, Ribeiro MAL, Castro GV de S, Menezes ALR, Lima RA, Silva RPM, et al. Retrospective study of the epidemiological overview of the transmission of Chagas disease in the State of Acre, South-Western Amazonia, from 2009 to 2016. Journal of Human Growth and Development. 2018;28(3):329–36.

8. Gomes SN. Helmintofauna parasitária de Dasypus novemcinctus (Xenarthra: Dasypodidae) no sul do Rio Grande do Sul, Brasil [Mestrado]. [Pelotas RS]: UNIVERSIDADE FEDERAL DE PELOTAS; 2010.

9. Curotto SMR, Silva T. G, Basso FZ, Barros Filho IR. Malária em mamíferos silvestres. Arq Ciênc Vet Zool UNIPAR, Umuarama,. 2012;15(1):67–77.

10. Rosa PS, Pinke CAE, Pedrini SCB, Silva EA. The effect of iron supplementation in the diet of Dasypus novemcinctus (Linnaeus, 1758) armadillos in captivity. Brazilian Journal of Biology. 2009;69(1).

11. Pedrini SCB. Pesquisa de Mycobacterium leprae e outras Micobactérias em Tatus Selvagens [DOUTORADO]. [Botucatu SP]: Universidade Estadual Paulista – UNESP; 2006.

12. Casanave EB, Polini NN. Comparative Study of Some Haematological Parameters of Two Wild Chaetophractus villosus (Mammalia, Dasypodidae) Populations. Comparative Haematology International. 1999;9:13–6.

13. Cuba Caparo A. Some hematologic and temperature determinations in the 7 banded armadillo (Dasypus hybridus). Lab Anim Sci. 1976;26(3).

14. D'Addamio GH, Walsh GP, Harris L, Borne R, Derouen MS. Hematologic parameters for wild and captive nine-banded armadillos (Dasypus novemcinctus). Lab Anim Sci. 1978;28(5).

15. Vasconcelos BM, Picanço FM da S, Castanho ÁAS, Rosa STP, Marques AR, Moraes W de NR, et al. Aspectos epidemiológicos da malária na Amazônia Legal, Brasil, 2000 a 2013. Brazilian Journal of Health Review. 2020;3(3):5230–43.

16. Rios-Velásquez CM, Martins-Campos KM, Simões RC, Izzo T, Dos Santos E V., Pessoa FA, et al. Experimental Plasmodium vivax infection of key Anopheles species from the Brazilian Amazon. Malar J. 2013;12(1).

17. Kluyber D, Desbiez ALJ, Attias N, Massocato GF, Gennari SM, Soares HS, et al. Zoonotic parasites infecting free-living armadillos from Brazil. Transbound Emerg Dis. 2021;68(3).

18. Noireau F. Wild Triatoma infestans, a potential threat that needs to be monitored. Mem Inst Oswaldo Cruz. 2009;104(SUPPL. 1).

19. Roque ALR, Jansen AM. Reservatórios do Trypanosoma cruzi e sua relação com os vetores. Em: Sociedade Brasileira de Zoologia, organizador. Vetores da doença de Chagas no Brasil [Internet]. Curitiba; 2014 [citado 8 de abril de 2025]. p. 75–87. Disponível em: http://books.scielo.org